



Letter to the Editor

The facts and misconceptions in hypospadias surgery



Dear Editor,

I read with great interest the article (in press) in the Journal of Pediatric Urology titled ‘Snodgrass Versus Snodgraft Operation To Repair The Distal Hypospadias In The Narrow Urethral Plate’ [1]. The authors discuss the narrow urethral plate with and without augmentation using the inner prepuce for the repair of distal penile hypospadias. They found no significant difference in complication rate in any group and concluded that one of them (Snodgraft) is not superior to other one (Snodgrass) in the narrow healthy urethral plate. If this study is accepted for comparison, I think it would be more logical to question both techniques than to accept the superiority of one over the other.

In both techniques, the authors attempt to obtain a wider glanular groove to form an easy-fitting neo-urethra by either incising deeply or grafting the ventral surface of the glans penis. Although it has never been mentioned, it is obvious that both techniques aim to provide the “fossa navicularis” of the male urethra, but have failed. Almost all hypospadias repair techniques include uniform tubularization of the neo-urethra over a catheter or stent. Furthermore, it is usually covered with a dartos flap up to the meatus. However, the male urethra is NOT a tubular structure with a uniform configuration and diameter due to the formation of the fossa navicularis within the glans penis. The fossa navicularis (glanular urethra) is not covered by

an additional layer as in the penile shaft, and actually has a delicate ventral wall [2,3]. The “septum glandis” and “frenulum” are involved in the formation of the ventral wall and give the glanular urethra a loose ventral support. Therefore the glans wings are separated ventrally by a thin fibrous tissue (septum glandis) and its epithelial extension (frenulum) [4]. We previously showed the normal anatomy of the glanular urethra and highlighted the importance of the presence of a septum (septum glandis) between the glans wings [5]. Moreover, the fossa navicularis and the septum glandis are never mentioned in hypospadias surgery, until the description of our technique (the Glanular Frenular Collar; GFC technique) [6,7]. The formation of a septum and frenulum ventrally as well as a frenular triangle or delta between the glans wings leads to a tension-free tubularization of the neo-urethra. Therefore, dissection of the glans wings and their approximation on the ventral midline to enclose the neo-urethra is a major misconception in hypospadias surgery [7]. In order to avoid meatal stenosis and/or glans dehiscence, a deep midline incision on the ventral surface of the glans penis is an important step both in the TIP (tubularised incised plate) repair technique and in the grafting procedure. However, this incision divides and damages the upper median portion of the septum glandis (corporo-glans ligament) which is supposed to provide flexibility and rigidity to the glans penis, especially during sexual intercourse [3] (Fig. 1).

A misconception is a view or opinion that is incorrect because of faulty thinking or understanding. Surgery should be based on more precise study of human anatomy and research studies should identify misconceptions that need to be replaced.

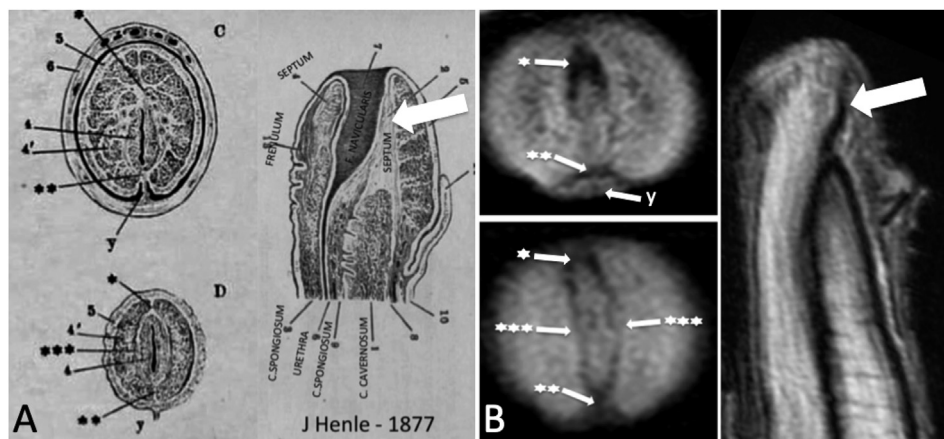


Figure 1 A) Dr Friedrich Gustav Jacob Henle's description of the median fibrous tissue surrounding the fossa navicularis as 'septum glandis' (***), its extensions as upper (*) and lower (**) median septum, and the frenulum (y). B) MR images of the penis show the same anatomical structures and the upper median septum, also known as the "distal ligament" or "corporo-glans ligament" (large arrow) [5].

Conflicts of interest

No conflict of interest.

References

- [1] Eldeeb M, Nagia S, Abau-Farha M, Hassan A. Snodgrass versus Snodgraft operation to repair the distal hypospadias in the narrow urethral plate. *J Pediatr Urol* 2020. <https://doi.org/10.1016/j.jpuro.2020.01.006>. in press.
- [2] Henle J. *Anatomischer Hand-Atlas zum Gebrauch im Secirsaal*. 1877. Band 6. Eingeweide. Braunschweig: Available via University Library Heidelberg, Available from: <https://digi.ub.uniheidelberg.de/diglit/henle1877bd6/0093/image>.
- [3] Özbey H. The mystery of Jacob Henle's 'septum glandis'. *J Anat* 2019;234:728–9. <https://doi.org/10.1111/joa.12965>.
- [4] Özbey H. Anatomical relationship between the foreskin and the urethra. *J Pediatr Urol* 2019;15:589–90. <https://doi.org/10.1016/j.jpuro.2019.06.027>.
- [5] Özbey H, Kumbasar A. Glans wings are separated ventrally by the septum glandis and frenulum penis: MRI documentation and surgical implications. *Turk J Urol* 2017;43:525e9. <https://doi.org/10.5152/tud.2017.00334>.
- [6] Özbey H, Etker S. Hypospadias repair with the glanular frenular collar (GFC) technique. *J Pediatr Urol* 2016;13:34. <https://doi.org/10.1016/j.jpuro.2016.09.016.e1-34>.
- [7] Özbey H. Response to the comment on 'Hypospadias repair with the glanular-frenular collar (GFC) technique'. *J Pediatr Urol* 2018;14:304–5. <https://doi.org/10.1016/j.jpuro.2018.02.009>.

Hüseyin Özbey*

Department of Pediatric Surgery, Division of Pediatric Urology, Istanbul Medical Faculty, Istanbul University, Istanbul

Department of Pediatric Surgery, Division of Pediatric Urology and Andrology, Sechenov First Moscow State Medical, University, (Sechenov University), Moscow, Russian Federation

*Corresponding author. Istanbul Medical Faculty, Department of Pediatric Surgery, Division of Pediatric Urology (Chairman), Istanbul University, Millet Caddesi, 34093 Istanbul, Turkey.

E-mail address: hozbey@istanbul.edu.tr

10 February 2020

Available online 30 April 2020